

CONNECTIVE TISSUE

CELLS:

- FIBROBLAST
- MACROPHAGE
- FAT CELL
- PLASMA CELL
- MAST CELL

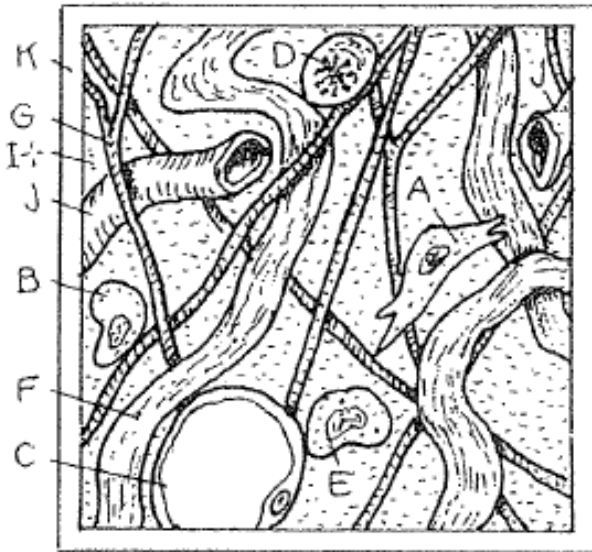FIBERS:

- COLLAGEN
- ELASTIC
- RETICULAR

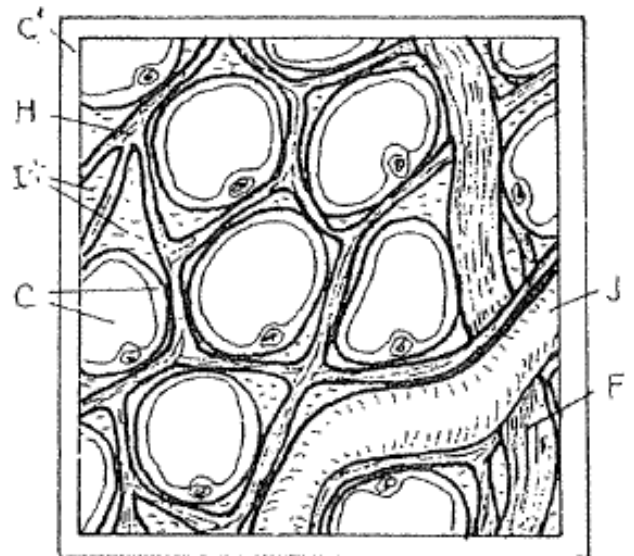
MATRIX,
GROUND SUBSTANCE

CAPILLARY


LOOSE, AREOLAR C.T. ^K



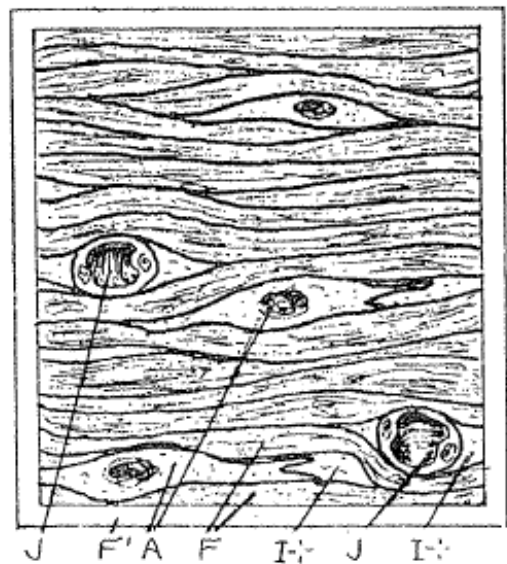
ADIPOSE C.T. ^{C'}



DENSE IRREGULAR C.T. ^F



DENSE REGULAR C.T. ^{F'}



SUPPORTING CONNECTIVE TISSUES

CARTILAGE

CHONDROCYTE_A

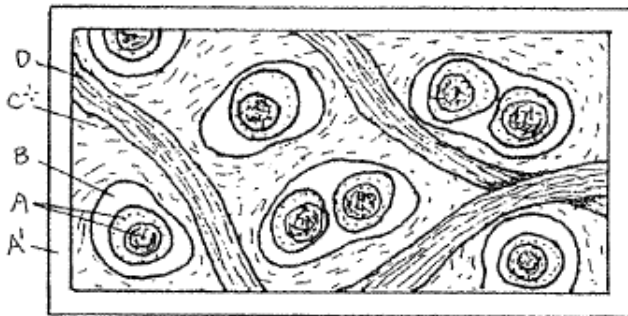
LACUNA_B

MATRIX_C

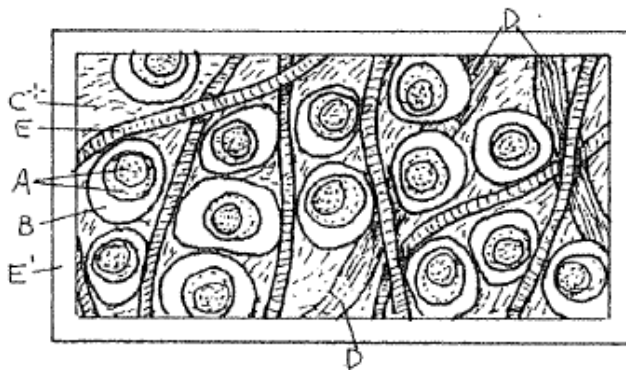
COLLAGEN FIBER_D

ELASTIC FIBER_E

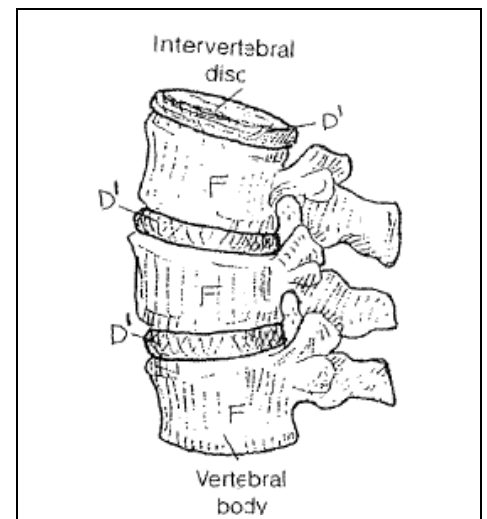
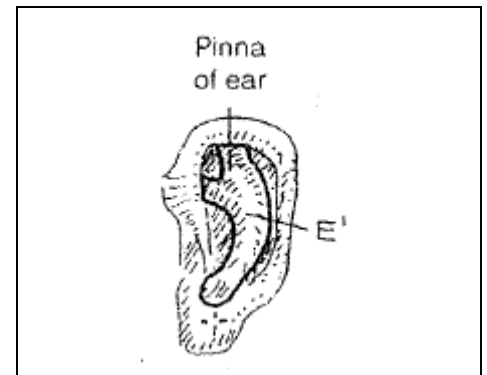
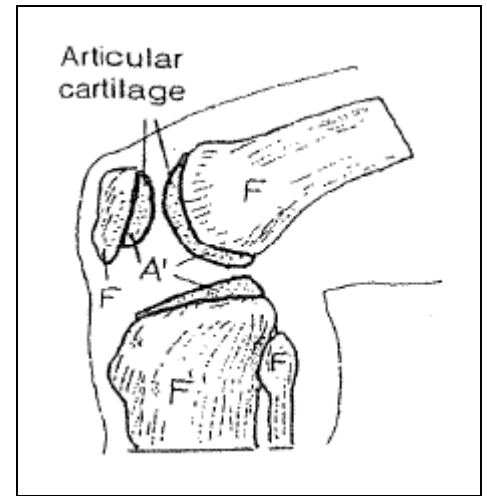
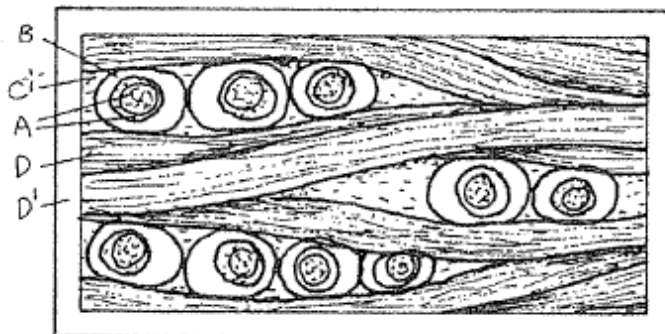
HYALINE CARTILAGE_{A'}



ELASTIC CARTILAGE_{E'}



FIBROCARILAGE_{D'}



BONE_F

PERIOSTEUM_{F'}

COMPACT BONE_G

HAVERSIAN SYS._{G*}

HAV. CANAL_H

LAMELLAE_{G'}

OSTEOCYTE_I

OSTEOCLAST_{I'}

LACUNA_F

CANALICULI_J

VOLKMANN CANAL_K

BLOOD VESSEL_L

SPONGY BONE_{G²}

